



Protocol for the Examination of Excision Specimens From Patients With Carcinoma of the Anus

Version: 5.0.0.0

Protocol Posting Date: September 2023

The use of this protocol is recommended for clinical care purposes but is not required for accreditation purposes.

This protocol may be used for the following procedures AND tumor types:

Procedure	Description
Excision	Includes excisional biopsy (polypectomy), local excision (transanal disk excision), and other biopsy
Tumor Type	Description
Carcinoma	Invasive carcinomas including small cell and large cell (poorly differentiated) neuroendocrine carcinoma

The following should NOT be reported using this protocol:

Procedure
Primary resection specimen with no residual cancer (e.g., following neoadjuvant therapy)
Cytologic specimens
Tumor Type
Lymphoma (consider the Hodgkin or non-Hodgkin Lymphoma protocols)
Gastrointestinal stromal tumor (GIST) (consider the GIST protocol)
Non-GIST sarcoma (consider the Soft Tissue protocol)
Rectal Adenocarcinoma

Authors

Lawrence J. Burgart, MD*; William V. Chopp, MD*; Dhanpat Jain, MD*.

With guidance from the CAP Cancer and CAP Pathology Electronic Reporting Committees.

* Denotes primary author.

Accreditation Requirements

The use of this biopsy case summary is recommended for clinical care purposes but is not required for accreditation purposes. The core and conditional data elements are routinely reported for biopsy specimens. Non-core data elements are indicated with a plus sign (+) to allow for reporting information that may be of clinical value.

CAP
Approved

Anus.Bx.TDE_5.0.0.0.REL_CAPCP

Summary of Changes

v 5.0.0.0

- Updated to AJCC Version 9
- Updated the position of “Distance from Invasive Carcinoma to Closest Mucosal Margin” question so that the question is only applicable if the answer “All margins negative for invasive carcinoma” is selected
- LVI question update from "Lymphovascular Invasion" to "Lymphatic and/or Vascular Invasion"
- pTNM Classification update

Reporting Template

Protocol Posting Date: September 2023

Select a single response unless otherwise indicated.

CASE SUMMARY: (ANUS: Local Excision)

Standard(s): AJCC-UICC 9

This case summary is recommended for reporting local excision and polypectomy specimens but is not required for accreditation purposes.

SPECIMEN

Specimen (select all that apply)

- Anal canal
- Anorectal junction
- Rectum
- Perianal skin
- Other (specify): _____
- Not specified

Procedure

- Excisional biopsy (polypectomy)
- Local excision (transanal disk excision)
- Other (specify): _____
- Not specified

Specimen Integrity (Note [A](#))

- Intact
- Fragmented
- +Number of Fragments**
- Specify number: _____
- Other (specify): _____
- Cannot be determined: _____
- Other (specify): _____

TUMOR

Tumor Site (Note [B](#))

- Anal canal: _____
- Perianal region: _____
- Anus, not otherwise specified: _____
- Other (specify): _____
- Unknown: _____

Histologic Type (Note [C](#))

- Squamous cell carcinoma
- Verrucous squamous cell carcinoma
- Adenocarcinoma
- Large cell neuroendocrine carcinoma
- Small cell neuroendocrine carcinoma

- Mixed neuroendocrine-non-neuroendocrine neoplasm
- Other histologic type not listed (specify): _____
- Carcinoma, type cannot be determined: _____

+Histologic Type Comment: _____

Histologic Grade (Note [D](#))

- G1, well differentiated
- G2, moderately differentiated
- G3, poorly differentiated
- G4, undifferentiated
- Other (specify): _____
- GX, cannot be assessed: _____
- Not applicable: _____

Tumor Size

- Greatest dimension in Centimeters (cm): _____ cm

+Additional Dimension in Centimeters (cm): ____ x ____ cm

- Cannot be determined (explain): _____

Tumor Extent (select all that apply)

- Carcinoma in situ
- Invades lamina propria
- Invades muscularis mucosae
- Invades submucosa
- Invades sphincter muscle
- Invades perianal skin
- Cannot be determined: _____
- No evidence of primary tumor

Treatment Effect (Note [E](#))

- No known presurgical therapy
- Present, with no viable cancer cells (complete response, score 0)
- Present, with single cells or rare small groups of cancer cells (near complete response, score 1)
- Present, with residual cancer showing evident tumor regression, but more than single cells or rare small groups of cancer cells (partial response, score 2)
- Present (not otherwise specified)
- Absent, with extensive residual cancer and no evident tumor regression (poor or no response, score 3)
- Cannot be determined: _____

+Lymphatic and / or Vascular Invasion

- Not identified
- Present
- Cannot be determined: _____

+Perineural Invasion

- Not identified
- Present
- Cannot be determined: _____

+Tumor Comment: _____

MARGINS

Margin Status for Invasive Carcinoma

___ All margins negative for invasive carcinoma

Distance from Invasive Carcinoma to Closest Deep Margin

Specify in Centimeters (cm)

___ Exact distance in cm: _____ cm

___ Greater than 1 cm

Specify in Millimeters (mm)

___ Exact distance in mm: _____ mm

___ Greater than 10 mm

Other

___ Other (specify): _____

___ Cannot be determined: _____

___ Not applicable

Distance from Invasive Carcinoma to Closest Mucosal Margin

Specify in Centimeters (cm)

___ Exact distance in cm: _____ cm

___ Greater than 1 cm

Specify in Millimeters (mm)

___ Exact distance in mm: _____ mm

___ Greater than 10 mm

Other

___ Other (specify): _____

___ Cannot be determined: _____

___ Not applicable

___ Invasive carcinoma present at margin

Margin(s) Involved by Invasive Carcinoma (select all that apply)

___ Deep: _____

___ Mucosal (specify location / clock position, if possible): _____

___ Other (specify): _____

___ Cannot be determined (explain): _____

___ Other (specify): _____

___ Cannot be determined (explain): _____

___ Not applicable

Margin Status for High-Grade Dysplasia (select all that apply)

___ All margins negative for high-grade dysplasia

___ High-grade dysplasia present at mucosal margin (specify location / clock position, if possible):

___ Other (specify): _____

___ Cannot be determined (explain): _____

___ Not applicable

+Margin Comment: _____

pTNM CLASSIFICATION (AJCC Version 9) (Note F)

Reporting of pT, pN, and (when applicable) pM categories is based on information available to the pathologist at the time the report is issued. As per the AJCC (Chapter 1, 8th Ed.) it is the managing physician's responsibility to establish the final pathologic stage based upon all pertinent information, including but potentially not limited to this pathology report.

Modified Classification (required only if applicable) (select all that apply)

- Not applicable
- y (post-neoadjuvant therapy)
- r (recurrence)

pT Category

- pT not assigned (cannot be determined based on available pathological information)
- pT0: No evidence of primary tumor
- pT1: Tumor less than or equal to 2 cm in greatest dimension
- pT2: Tumor greater than 2 cm but less than or equal to 5 cm in greatest dimension
- pT3: Tumor greater than 5 cm in greatest dimension
- pT4: Tumor of any size invading adjacent organ(s), such as the vagina, urethra, or bladder

T Suffix (required only if applicable)

- Not applicable
- (m) multiple primary synchronous tumors in a single organ

ADDITIONAL FINDINGS

+Additional Findings (Note G) (select all that apply)

- None identified
- Crohn disease
- Condyloma acuminatum
- Anal fistula
- Squamous intraepithelial lesion
- Associated rectal carcinoma (Paget disease)
- Other (specify): _____

SPECIAL STUDIES

+Ancillary Studies (Note H)

- Specify: _____
- Not performed

COMMENTS

Comment(s): _____

Explanatory Notes

A. Specimen Integrity and Handling

For specimens from local excision procedures, all relevant margins, including the deep resection margin, should be inked. Evaluation of margins and invasion is facilitated if the specimen is pinned before fixation in formalin.

B. Location

Documentation of tumor location within the anal canal is important for purposes of stage assignment. The regional lymph nodes at risk of metastasis are different for cancers of the anal canal, the rectum, and the perianal skin. Currently, most anal canal carcinomas are managed successfully without surgery, using combination chemotherapy and radiation therapy,¹ and resection specimens of anal tumors are seen only infrequently (primarily for small anal margin lesions or after failure of other treatment modalities). Although histological diagnosis is almost always performed on small biopsies, determination of the primary tumor location from biopsy specimens may be difficult or impossible. Therefore, documentation of anatomic site often requires clinical correlation.

The anal canal begins where the rectum enters the puborectalis sling at the apex of the anal sphincter complex (palpable as the anorectal ring on digital rectal examination and approximately 1 cm to 2 cm proximal to the dentate line) and ends with the squamous mucosa blending with the perianal skin (Figure 1), which coincides roughly with the palpable intersphincteric groove or the outermost boundary of the internal sphincter muscle, easily visualized on endoanal ultrasound.² The anus encompasses true mucosa of three different histologic types: glandular, transitional, and squamous (proximal to distal, respectively). The most proximal aspect of the anal canal is lined by colorectal mucosa in which squamous metaplasia may occur. When involved by metaplasia, this zone also may be referred to as the transformation zone. Immediately proximal to the macroscopically visible dentate line, a narrow zone of multilayered transitional mucosa is variably present. In the region of the dentate line, anal glands are subjacent to the mucosa, often penetrating through the internal sphincter into the intersphincteric plane. The distal zone of the anal canal extends from the dentate line to the mucocutaneous junction with the perianal skin and is lined by a nonkeratinizing squamous epithelium devoid of epidermal appendages (hair follicles, apocrine glands, and sweat glands).

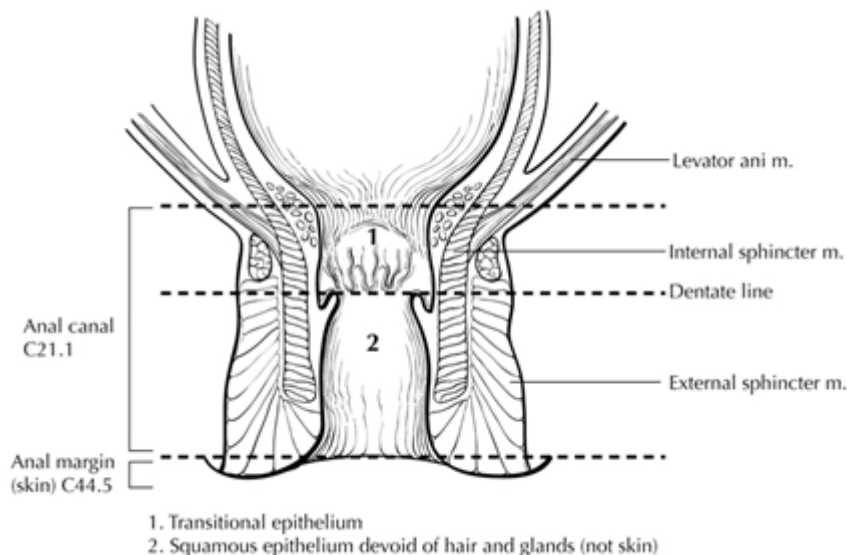


Figure 1. Anatomy of the anal canal. From Greene et al.³ Used with permission of the American Joint Committee on Cancer (AJCC), Chicago, Illinois. The original source for this material is the *AJCC Cancer Staging Atlas* (2006) published by Springer Science and Business Media LLC, www.springerlink.com. This protocol applies to tumors involving the anal canal and perianal region (Figure 2). Tumors arising in the anal canal (including all three types of mucosa) that cannot be entirely visualized by gentle traction placed on the buttocks are considered as anal cancers, while tumors arising in the skin at or distal to the squamous mucocutaneous junction, can be entirely visualized with gentle traction placed on the buttocks, and are within 5cm of the anus are considered perianal cancers. For tumors that are localized to the perineal region and not obviously arising from anus or vulva, should be classified as “favor perianal” or “favor vulvar” based on clinical assessment. This protocol does not apply to tumors that are >5 cm from the anus.

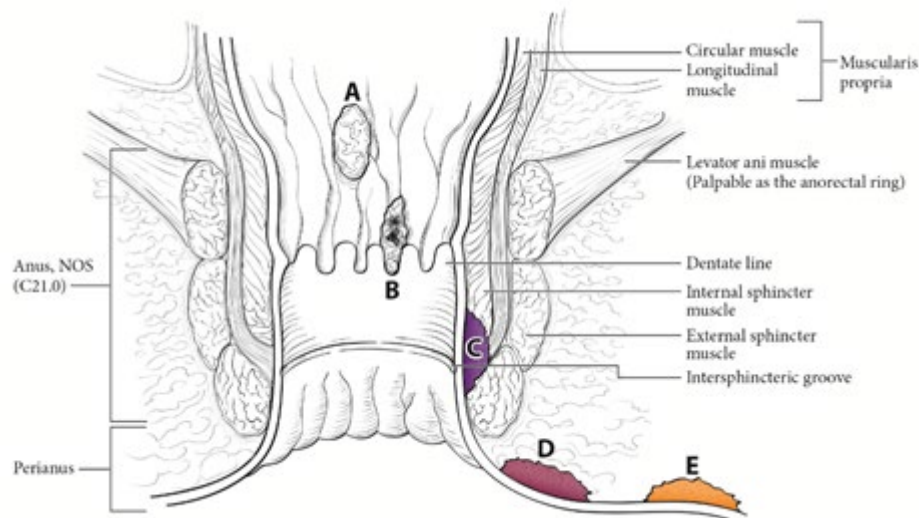


Figure 2. Anal cancer (A–C), perianal cancer (D), and skin cancer (E) as visualized with gentle traction placed on the buttocks. From Amin et al.² Used with the permission of the American Joint Committee on Cancer (AJCC), Chicago, Illinois. The original source for this material is the *AJCC Cancer Staging Manual* (2016) published by Springer Science and Business Media LLC, www.springerlink.com.

References

1. Engstrom PF, Benson AB 3rd, Chen Y-J, et al. Anal canal cancer clinical practice guidelines in oncology. *J Natl Compr Cancer Netw*. 2005;3(4):510-515.
2. Amin MB, Edge SB, Greene FL, et al, eds. *AJCC Cancer Staging Manual*. 8th ed. New York, NY: Springer; 2017.
3. Greene FL, Compton, CC, Fritz AG, et al, eds. *AJCC Cancer Staging Atlas*. New York: Springer; 2006.

C. Histologic Type

For consistency in reporting, the histologic classification proposed by the World Health Organization (WHO) is recommended.¹ However, this protocol does not preclude the use of other systems of classification or histologic types.

The great majority of carcinomas of the anus are squamous cell carcinomas.² The previous edition of the WHO classification included 3 subtypes of squamous cell carcinoma (SCC): large cell keratinizing, large cell nonkeratinizing, and basaloid. However, because most SCCs of the anal canal show more than 1

subtype, the diagnostic reproducibility of these subtypes has been low. Furthermore, no significant prognostic differences between subtypes have consistently been established, although the basaloid subtype of squamous cell carcinoma may be associated with a higher risk of distant metastasis.³ Therefore, the WHO now recommends that the generic diagnostic term “squamous cell carcinoma” be used for all squamous malignancies of the anal canal. However, additional descriptive comment regarding specific histologic features, such as predominant cell size, basaloid features, degree of keratinization, or adjacent intraepithelial neoplasia, is encouraged. Prominent basaloid features and small tumor cell size are related to infection with “high-risk” human papillomavirus.¹ SCC with a predominantly basaloid differentiation pattern was formerly known as cloacogenic carcinoma, but this term is now considered obsolete.

Two variants of SCC of the anal canal deserve note because they differ in prognosis from typical squamous tumors. One is verrucous carcinoma (also known as giant condyloma or Buschke-Lowenstein tumor), which resembles a condyloma macroscopically but is larger and fails to respond to conservative therapy. Endophytic growth is present in verrucous carcinoma, but true invasive growth pattern is not present. These lesions are regarded as biologic intermediates between condylomas and SCCs, with a better prognosis than SCC. Unlike SCC, most of which are associated with HPV16, most verrucous carcinomas are associated with HPV types 6 and 11. Another important variant is SCC with mucinous microcysts (well-formed cystic spaces containing Alcian blue- or PAS-stainable mucin). This entity has an unfavorable prognosis as compared with that of SCC.¹

Finally, 2 rare types of anal canal carcinoma, anaplastic carcinoma and small cell carcinoma (high-grade neuroendocrine carcinoma), are tumors with aggressive biologic behavior and an unfavorable prognosis when compared with typical SCC. Tumors of the more distal anal canal and perianal region are generally purely squamous in type and show fewer basaloid or glandular features.

Based on the Lower Anogenital Squamous Terminology (LAST) project, a 2-tiered nomenclature is now recommended for noninvasive squamous proliferations of the anal canal: low-grade squamous intraepithelial lesion (LSIL), which includes low-grade dysplasia or anal intraepithelial neoplasia I; and high-grade squamous intraepithelial lesion (HSIL), which includes moderate- and high-grade dysplasia or anal intraepithelial neoplasia II and III, as well as carcinoma in situ.⁴

References

1. WHO Classification of Tumours Editorial Board. *Digestive system tumours*. Lyon (France): International Agency for Research on Cancer; 2019. (WHO classification of tumours series, 5th ed.; vol. 1).
2. Hatzaras I, Abir F, Kozol R, Sullivan P, Longo WE. The demographics, histopathology and patterns of treatment of anal cancer in Connecticut: 1980-2000. *Conn Med*. 2005;69(5):261-265.
3. Das P, Bhatia S, Eng C, et al. Predictors and patterns of recurrence after definitive chemoradiation for anal cancer. *Int J Radiat Oncol Biol Phys*. 2007;68(3):794-800.
4. Darragh TM, Colgan TJ, Cox JT, et al; Members of LAST Project Work Groups. The Lower Anogenital Squamous Terminology Standardization Project for HPV-Associated Lesions: background and consensus recommendations from the College of American Pathologists and the American Society for Colposcopy and Cervical Pathology. *Arch Pathol Lab Med*. 2012;136(10):1266-1297.

D. Histologic Grade

Histologic grades for anal canal squamous carcinoma are as follows:

Grade X	Grade cannot be assessed
Grade 1	Well differentiated

Grade 2 Moderately differentiated
Grade 3 Poorly differentiated

If there are variations in the differentiation within the tumor, the highest (least favorable) grade is recorded as the overall grade.

Histologic grades for adenocarcinoma of the anal canal based on the proportion of gland formation by the tumor are suggested as follows:

Grade X Grade cannot be assessed
Grade 1 Well differentiated (greater than 95% of tumor composed of glands)
Grade 2 Moderately differentiated (50% to 95% of tumor composed of glands)
Grade 3 Poorly differentiated (less than 50% of tumor composed of glands)

Tumors with no squamous, glandular or neuroendocrine differentiation (undifferentiated carcinomas by WHO classification) are categorized as grade 4. These grading schemes are not applicable to poorly differentiated neuroendocrine carcinomas.

E. Treatment Effect

Response of tumor to previous chemotherapy or radiation therapy should be reported. Although grading systems for tumor response have not been established, 3-category systems generally provide good interobserver reproducibility.¹ The following system is suggested:

Modified Ryan Scheme for Tumor Regression Score²

Description	Tumor Regression Score
No viable cancer cells (complete response)	0
Single cells or rare small groups of cancer cells (near complete response)	1
Residual cancer with evident tumor regression, but more than single cells or rare small groups of cancer cells (partial response)	2
Extensive residual cancer with no evident tumor regression (poor or no response)	3

References

1. Ryan R, Gibbons D, Hyland JMP, et al. Pathological response following long-course neoadjuvant chemoradiotherapy for locally advanced rectal cancer. *Histopathology*. 2005;47:141-146.
2. Darragh TM, Colgan TJ, Cox JT, et al; Members of LAST Project Work Groups. The Lower Anogenital Squamous Terminology Standardization Project for HPV-Associated Lesions: background and consensus recommendations from the College of American Pathologists and the American Society for Colposcopy and Cervical Pathology. *Arch Pathol Lab Med*. 2012;136(10):1266-1297.

F. TNM and Anatomic Stage/Prognostic Groupings

The TNM staging system for anal carcinoma of the American Joint Committee on Cancer (AJCC) and the International Union Against Cancer (UICC) is recommended by the protocol and shown below.¹ The primary tumor is staged according to its size and local extension, as determined by clinical or pathologic examination. The staging system applies to all carcinomas arising in the anal canal, including carcinomas that arise within anorectal fistulas and anal glands, but excluding melanomas, low-grade neuroendocrine tumors (carcinoid tumors), and sarcomas.

By AJCC/UICC convention, the designation “T” refers to a primary tumor that has not been previously treated. The symbol “p” refers to the pathologic classification of the TNM, as opposed to the clinical

classification, and is based on gross and microscopic examination. pT entails a resection of the primary tumor or biopsy adequate to evaluate the highest pT category, pN entails removal of nodes adequate to validate lymph node metastasis, and pM implies microscopic examination of distant lesions. Clinical classification (cTNM) is usually carried out by the referring physician before treatment during initial evaluation of the patient or when pathologic classification is not possible.

Pathologic staging is usually performed after surgical resection of the primary tumor. Pathologic staging depends on pathologic documentation of the anatomic extent of disease, whether or not the primary tumor has been completely removed. If a biopsied tumor is not resected for any reason (eg, when technically infeasible) and if the highest T and N categories or the M1 category of the tumor can be confirmed microscopically, the criteria for pathologic classification and staging have been satisfied without total removal of the primary cancer.

TNM Descriptors

For identification of special cases of TNM or pTNM classifications, the “m” suffix and “y,” “r,” and “a” prefixes are used. Although they do not affect the stage grouping, they indicate cases needing separate analysis.

The “m” suffix indicates the presence of multiple primary tumors in a single site and is recorded in parentheses: pT(m)NM.

The “y” prefix indicates those cases in which classification is performed during or after initial multimodality therapy (ie, neoadjuvant chemotherapy, radiation therapy, or both chemotherapy and radiation therapy).

The cTNM or pTNM category is identified by a “y” prefix. The ycTNM or ypTNM categorizes the extent of tumor actually present at the time of that examination. The “y” categorization is not an estimate of tumor before multimodality therapy (ie, before initiation of neoadjuvant therapy).

The “r” prefix indicates a recurrent tumor when staged after a documented disease-free interval and is identified by the “r” prefix: rTNM.

The “a” prefix designates the stage determined at autopsy: aTNM.

T Category Considerations

T categories for anal canal cancer are illustrated in Figures 3 through 6.

T1

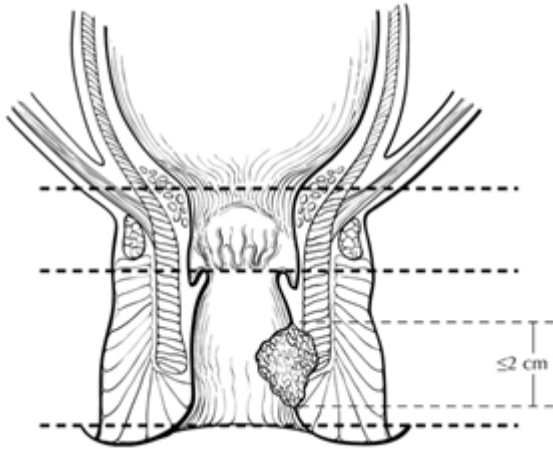


Figure 3. T1 is defined as tumor 2 cm or less in greatest dimension. From Greene et al.² Used with permission of the American Joint Committee on Cancer (AJCC), Chicago, Illinois. The original source for this material is the *AJCC Cancer Staging Atlas* (2006) published by Springer Science and Business Media LLC, www.springerlink.com.

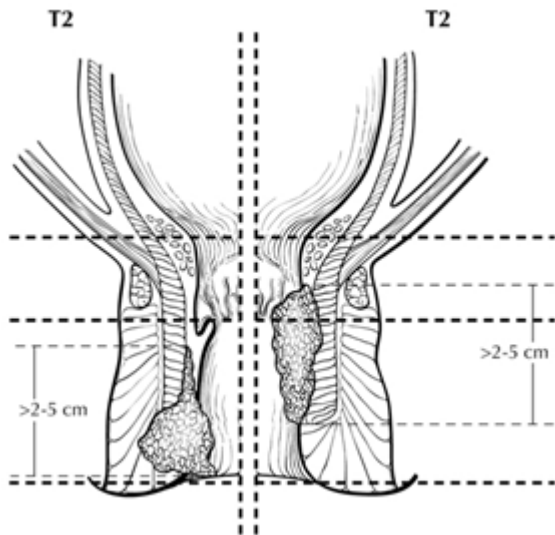


Figure 4. T2 is defined as tumor measuring more than 2 cm but 5 cm or less in greatest dimension. From Greene et al.² Used with permission of the American Joint Committee on Cancer (AJCC), Chicago, Illinois. The original source for this material is the *AJCC Cancer Staging Atlas* (2006) published by Springer Science and Business Media LLC, www.springerlink.com.

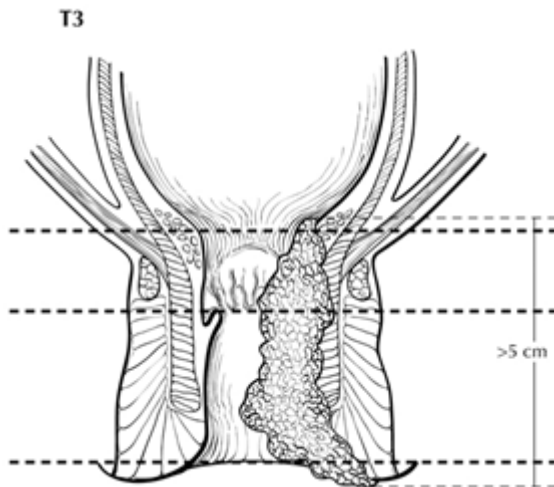


Figure 5. T3 is defined as tumor measuring more than 5 cm in greatest dimension. From Greene et al.² Used with permission of the American Joint Committee on Cancer (AJCC), Chicago, Illinois. The original source for this material is the *AJCC Cancer Staging Atlas* (2006) published by Springer Science and Business Media LLC, www.springerlink.com.

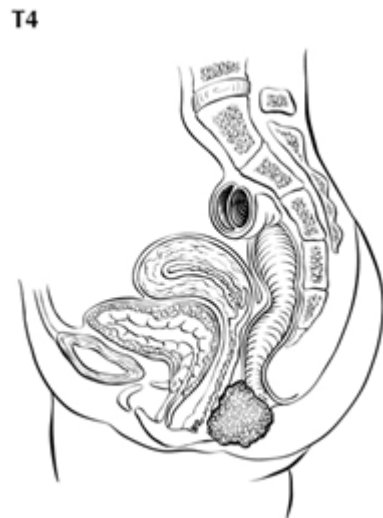

Figure 6. T4 is defined as tumor of any size invading adjacent organs such as vagina (illustrated), urethra, or bladder. From Greene et al.² Used with permission of the American Joint Committee on Cancer (AJCC), Chicago, Illinois. The original source for this material is the *AJCC Cancer Staging Atlas* (2006) published by Springer Science and Business Media LLC, www.springerlink.com.

Vessel Invasion

By AJCC/UICC convention, vessel invasion (lymphatic or venous) does not affect the T category indicating local extent of tumor unless specifically included in the definition of a T category.

References

1. Amin MB, Edge SB, Greene FL, et al, eds. *AJCC Cancer Staging Manual*. 8th ed. New York, NY: Springer; 2017.

2. Greene FL, Compton, CC, Fritz AG, et al, eds. *AJCC Cancer Staging Atlas*. New York: Springer; 2006.

G. Additional Findings

Predisposing conditions to anal canal carcinoma that may be found in the pathologic specimen include condyloma accuminatum associated with human papilloma virus infection.¹ Squamous intraepithelial neoplasia is recognized as a precursor lesion for squamous cell carcinoma of the anal canal,² and its presence should be reported. Both adenocarcinomas and squamous cell carcinomas have been reported in the setting of chronic anorectal fistulae arising in long-standing Crohn disease,³ although the association of benign inflammatory lesions and anal cancer remains controversial.^{4,5}

References

1. Daling JR, Madeleine MM, Johnson LG, et al. Human papillomavirus, smoking, and sexual practices in the etiology of anal cancer. *Cancer*. 2004;101(2):270-280.
2. Shepherd NA. Anal intraepithelial neoplasia and other neoplastic precursor lesions of the anal canal and perianal region. *Gastroenterol Clin North Am*. 2007;36(4):969-987.
3. Ky A, Sohn H, Weinstein MA, Korelitz BI. Carcinoma arising in anorectal fistulas of Crohn's disease. *Dis Colon Rectum*. 1998;41:992-996.
4. Frisch M, Olsen JH, Bautz A, Melbye M. Benign anal lesions and the risk of anal cancer. *N Engl J Med*. 1994;331:300-302.
5. Nordenvall C, Nyren O, Ye W. Elevated anal squamous cell carcinoma risk associated with benign inflammatory anal lesions. *Gut*. 2006;55(5):703-707.

H. Ancillary Studies

Immunohistochemistry may be helpful in establishing tumor type for poorly differentiated carcinomas; squamous cell carcinomas of the anal canal express cytokeratin (CK) 7, CK5/6, p53,¹ and p63² but are negative for CK20. In contrast, anal gland carcinomas are mucin positive and express CK 20 and CK7 but are negative for CK5/6 and p63.^{1,2,3}

Immunohistochemical studies may also aid in distinguishing primary anal Paget disease from secondary Paget disease of the perianal area, which is associated with colorectal and anal canal carcinoma. CK7 expression is a sensitive method for detection of both primary and secondary Paget cells within involved anal and perianal epithelium. In addition, however, the specific immunophenotype of Paget cells has been shown to correlate with pathogenesis and may be important in patient management. Demonstration of CK20 expression has been shown to identify Paget disease that is likely to be associated with underlying rectal adenocarcinoma (presenting either synchronously or metachronously). In contrast, Paget cells that do not express CK20 but instead are positive for gross cystic disease fluid protein (GCDFP), a marker for apocrine differentiation, are likely to represent primary cutaneous intraepithelial malignancy.^{4,5,6}

References

1. Balachandra B, Marcus V, Jass JR. Poorly differentiated tumours of the anal canal: a diagnostic strategy for the surgical pathologist. *Histopathology*. 2007;50(1):163-174.
2. Owens SR, Greenson JK. Immunohistochemical staining for p63 is useful in the diagnosis of anal squamous cell carcinomas. *Am J Surg Pathol*. 2007;31(2):285-290.
3. Lisovsky M, Patel K, Cymes K, Chase D, Bhuiya T, Morgenstern N. Immunophenotypic characterization of anal gland carcinoma: loss of p63 and cytokeratin 5/6. *Arch Pathol Lab Med*. 2007;131(8):1304-1311.

4. WHO Classification of Tumours Editorial Board. *Digestive system tumours*. Lyon (France): International Agency for Research on Cancer; 2019. (WHO classification of tumours series, 5th ed.; vol. 1).
5. Shepherd NA. Anal intraepithelial neoplasia and other neoplastic precursor lesions of the anal canal and perianal region. *Gastroenterol Clin North Am*. 2007;36(4):969-987.
6. Goldblum JR, Hart WR. Perianal Paget's disease: a histologic and immunohistochemical study of 11 cases with and without associated rectal adenocarcinoma. *Am J Surg Pathol*. 1998;22:170-179.